

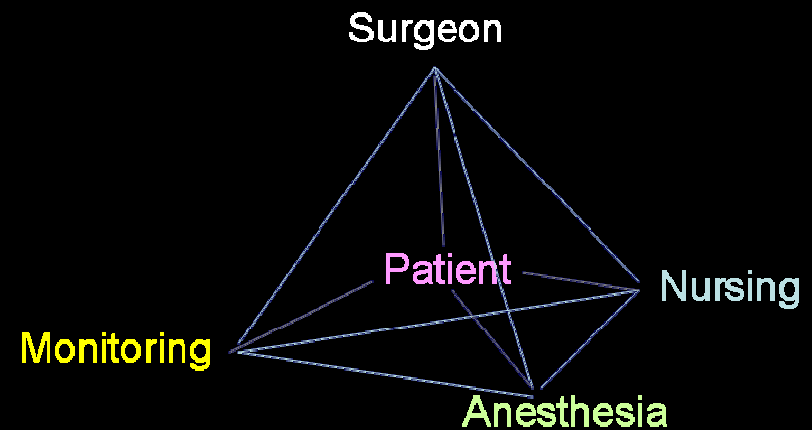
INTRA-OPERATIVE NEUROPHYSIOLOGICAL MONITORING

Moderators

Dr PSC/SS

Presented by

Dr Amol Raheja



Intra-op Neurophysiological Monitoring

- Real time feed-back information to the surgical team about the functional status of neural pathways under surgical manipulation
 - ▣ preventive or corrective actions to avoid irreversible injuries.
 - ▣ Team of Neurosurgeon, Neurophysiologist and neuroanesthesiologist is ideal.
- Ideal Technique –
 - ▣ High Sensitivity
 - ▣ High Specificity
 - ▣ Low invasiveness
 - ▣ Ease of use

HISTORY-Spinal

1970-
aggressive
spinal
technology

1972-
Tetsuya
Tamaki
group from
Japan --
utilize SCEP

Nash from
USA-- SSEP

1973
Wake up test:
Vauzelle and
Stagna

1983:
National
Orthopaedic
Hospital
group(UK)-
SSEP

Late 1980s:
motor tract
monitoring--
Merton and
Merton

History – EEG and ECOG

- Han Berger in 1928-29 was the first to report EEG tracings from human brains.
- The first use of intraoperative EEG was by Foerster and Alternberger in 1935.
- In the late 1930s through the 1950s, Herbert Jasper and Wilder Penfield further developed this technique, using ECoG for localization and surgical treatment of epilepsy.
- They also performed careful mapping of cortical function by direct electrical stimulation.

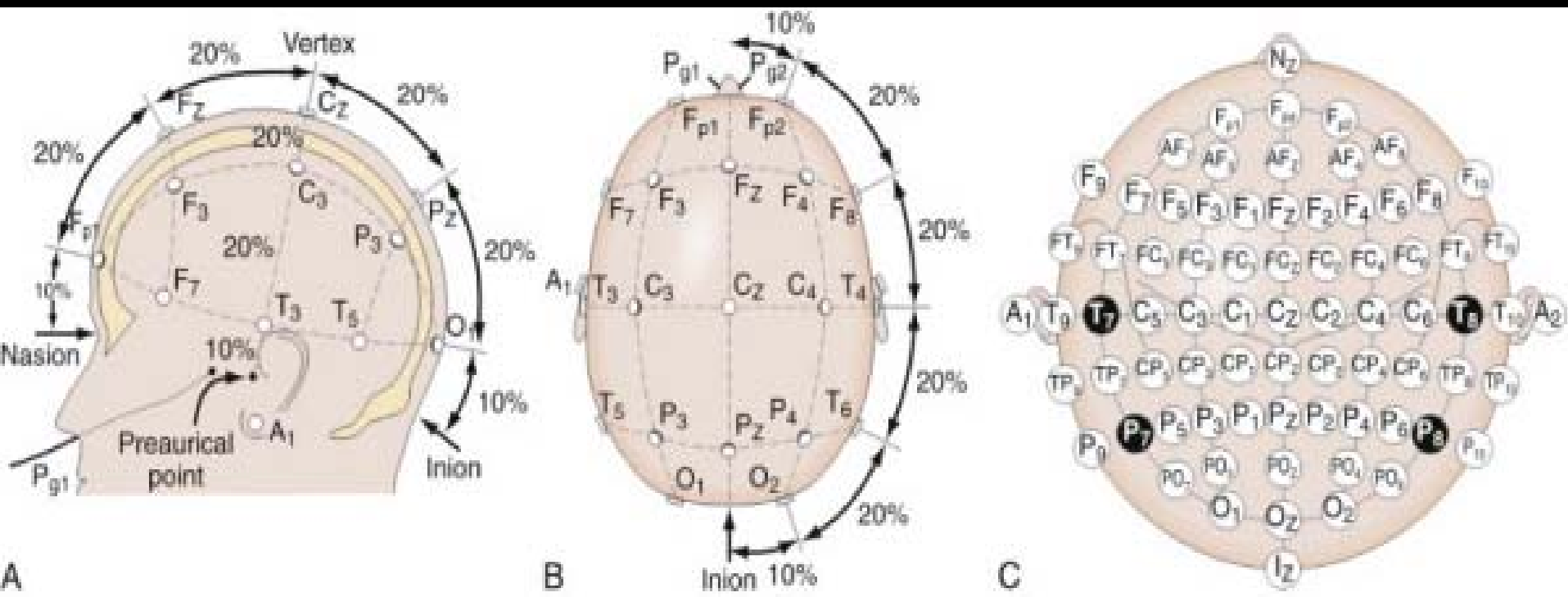
Methods

- **SSEP**: somatosensory evoked potential after stimulation of a peripheral nerve
- **Spinal MEP**: spinal cord evoked potential after stimulation of the motor cortex
- **Muscle MEP (brain)**: muscle evoked potential after stimulation of the motor cortex
- **Muscle MEP (spinal cord)**: muscle evoked potential after stimulation of the spinal cord
- **EMG** : Muscle evoked potential after stimulation of peripheral nerves
- **ECOG** : is the practice of using electrodes placed directly on the exposed surface of the brain to record electrical activity from the cerebral cortex
- **Scalp EEG** : Surface recording of cortical activity of brain

Somato-sensory Evoked Potential

- Monitors Dorsal column integrity
- Most commonly used technique in spine surgery
- Stimulation sites UL – Median/Ulnar nerves
LL -- Posterior tibial nerve
- Excitatory controlled repetitive action potentials propagating from peripheral nerves to dorsal roots, posterior column and finally to contralateral sensory cortex
- Stimulation waveforms – 250 us square wave pulse trains at 4.7 Hz and 20-40 mA stimulation amplitudes
- Recording scalp electrodes – follow 10-20 system (Standardized by American Electroencephalographic society)

The international 10-20 system seen from the left (A) and above the head (B). A, ear lobe; C, central; F, frontal; F_p, frontal polar; P, parietal; P_g, nasopharyngeal; O, occipital. C, Location and nomenclature of the intermediate 10% electrodes, as standardized by the American Electroencephalographic Society.



SSEP Contd..

- Neural stimulation of the lower extremities also checks integrity of spinocerebellar tracts, which involve the dorsal nucleus of Clarke's column between T1 and L2.
- Comparison is made with the post-induction baseline measurements.
- $\geq 50\%$ decrease in amplitude and associated 10% increase in latency – significant
- Non-surgical variables – Depth of anesthesia, Temp., and MAP
- Signals – Subcortical : Lower amplitude and reduced signal to noise ratio but more resistant to depth of anesthesia
Cortical : Larger amplitude and higher signal to noise ratio (Tend to be more reliable electrically) but more sensitive to depth of anesthesia
- Disadvantage – Motor deficits can not be predicted.

Motor Evoked Potential (MEP)

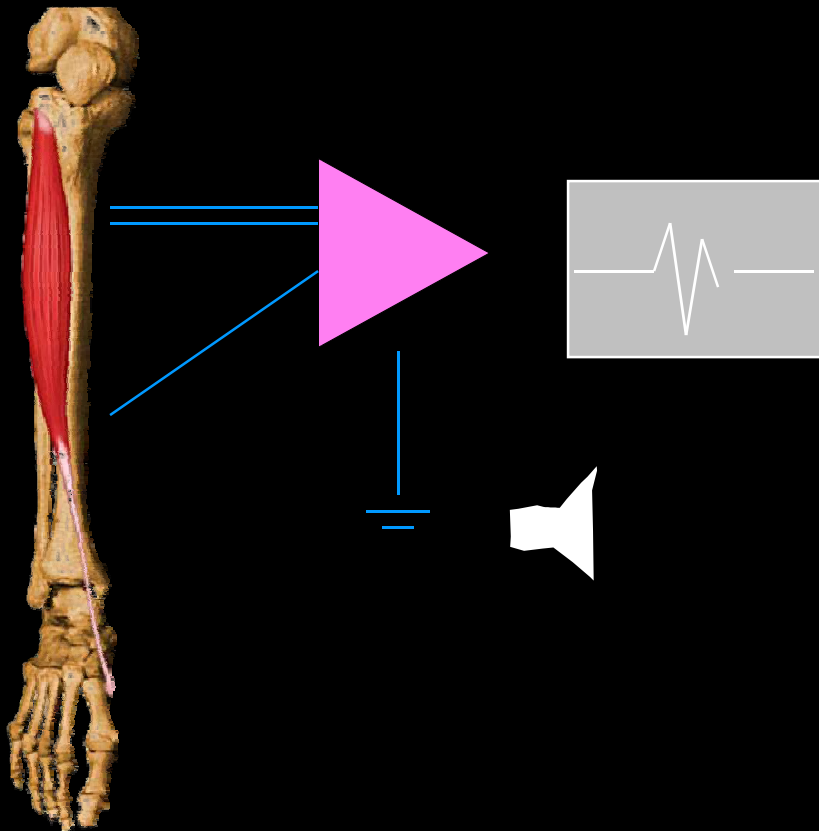
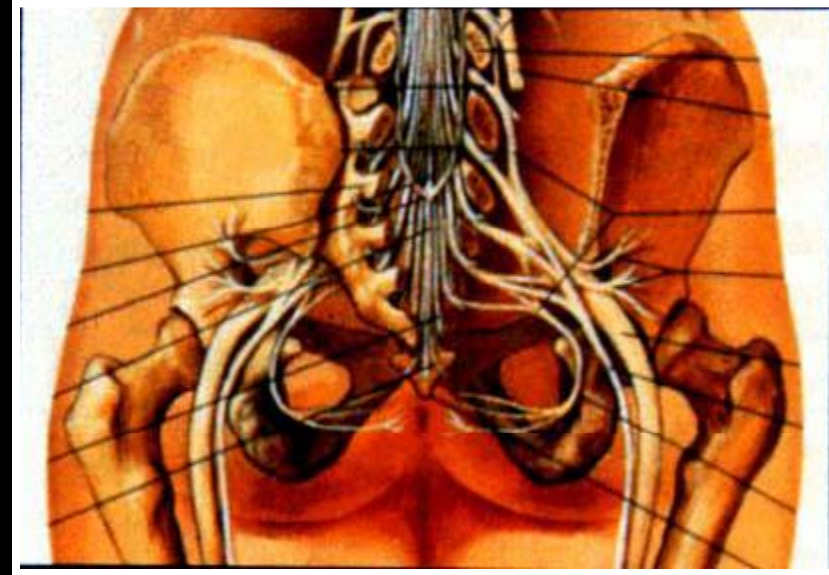
- Transcranial electrical/ magnetic stimulation of the cerebral motor cortex causes muscle activation.
- Role in Intramedullary tumors and procedures with a risk for vascular compromise of anterior spinal artery.
- Scalp electrodes are placed according to 10-20 system.
- D-waves (Direct)– Single pulse stimulation and corticospinal tract readings
- I- Waves (Indirect)- Resultant waves from ascending vertically oriented excitatory chains of neurons terminating on cortical motor neurons – Abolished by anesthetic agents.
- Recording of D-waves by Epidural electrodes – placed cranially and caudally to op site.

MEP Contd..

- Reduction of $\geq 50\%$ in D-wave amplitude have been shown to correlate with new post-operative deficits.
- CMAPs – Multipulse stimulation techniques – short pulse trains are used
- Recordings of CMAP done at thenar muscles/ tibialis anterior
- CMAPs Monitors Both Cortico-spinal tracts and distal muscle functional units including NM junction
- Myogenic MEPs are interpreted as all or none phenomenon

ElectroMyoGraphy

SSEP cannot
evaluate individual
nerve roots



- Operative Monitoring
 - Nerve irritation
 - Nerve identification (stimulation)
 - Pedicle screw testing
 - Reflex testing
 - (Motor evoked potentials)

Electromyography (EMG)

- Types – Continuous/ Triggered
- Sensitive to surgical manipulation of peripheral nerves – spinal surgeries with risk of radicular injury (TCS/Ped. Screw fixation)
- Continuous EMG – Paired stainless steel needle electrodes insulated to within 5 mm of the tip and transdermally inserted into the target muscle
- Electrode impedance below 5 k Ω and interelectrode impedance below 1 k Ω acceptable
- Morphology of EMG – Spikes : individual discharges
 - Bursts : Brief bundles of discharges
 - Train activity: Persistently regular repeated discharge patterns
 - Neurotonic discharges : Persistent prolonged bursting
- Sustained activity (> 2 sec) -- significant

Triggered/Evoked EMG

- Obtained from suspicious tissues – scar, tumor, filum
- Reflects functional integrity between interrogated tissue and muscle units being recorded.
- Stimulation – Bipolar probe delivers monophasic square wave pulses of 3 Hz, duration 100 microsec and a constant current source less than 10 mA
- Continuous EMG has high sensitivity but low specificity in predicting post-operative neurological deficits.

Which Nerves?

Cervical

C2, C3, C4

Trapezius, Sternocleidomastoid
Spinal portion of the spinal accessory n.

C5, C6

Biceps, Deltoid

C6, C7

Flexor Carpi Radialis

C8, T1

Abductor Pollicis Brevis, Abductor
Digiti Minimi

Thoracic

T5, T6

Upper Rectus Abdominis

T7, T8

Middle Rectus Abdominis

T9, T10, T11

Lower Rectus Abdominis

T12

Inferior Rectus Abdominis

Lumbosacral

L2, L3, L4

Vastus Medialis

L4, L5, S1

Tibialis Anterior

L5, S1

Peroneus longus

Sacral

S1, S2

Gastrocnemius

S2, S3, S4

External anal sphincter

Comparison

MODALITIES	SSEPs	MEPs/CMAPs	EMG
Stimulation	Peripheral sensory nerves	Transcranial scalp electrodes	Free-running: none Triggered: bipolar stimulation of a specific structure
Recording	Cortical and cervicomedullary junction	Extremity muscles (e.g., thenar muscles, tibialis anterior)	Myotome specific
Alert threshold	50% reduction in amplitude 10% increase in latency	Disappearance of signal (all-or-none phenomenon)	Sustained activity (>2 sec)

MODALITIES	SSEPs	MEPs/CMAPs	EMG
Advantages	<p>Specific and sensitive to sensory deficits</p> <p>Continuous monitoring, no interruption in surgical manoeuvres</p>	<p>Specific and sensitive to motor deficits</p> <p>Large signal amplitude, instantaneous feedback</p>	<p>Allows surgical correlation with specific nerve roots</p> <p>Continuous monitoring</p> <p>Instantaneous feedback</p>
Disadvantages	<p>False-negative results for motor deficits</p> <p>Low signal amplitude, multitrace averaging required, delayed response (seconds to minutes)</p>	<p>Total intravenous anaesthesia</p> <p>Intermittent monitoring, interruption in surgery required</p>	<p>No neuromuscular blockade</p> <p>Monitors only nerve roots</p>

References – SSEP & EMG

- Reciprocal sensitivity and specificity of SSEPs and EMG in thoraco-lumbar spine surgeries –
SSEP – Sensitivity 28.6% and Specificity 94.7 %
EMG – Sensitivity 100 % and Specificity 23.7 %

** Gunnarsson T et al: Real-time continuous intraoperative electromyographic and somatosensory evoked potential recordings in spinal surgery: Correlation of clinical and electrophysiologic findings in a prospective, consecutive series of 213 cases. *Spine* 2004; 29:677-684.

SSEP in Endoscopic endonasal approach

- The incidence of changes in SSEP during the procedure was 20 of 976 (2%). The incidence of new postoperative neurological deficits was 5 of 976 (0.5%). The positive and negative predictive values of SSEPs during EEA to predict neurovascular deficits were 80.00% and 99.79%, respectively.

Neurosurgery. 2011 Sep;69(1 Suppl Operative):ons64-76; discussion ons76.

Somatosensory evoked potential monitoring during endoscopic endonasal approach to skull base surgery: analysis of observed changes.

Thirumala PD Department of Neurological Surgery, University of Pittsburgh, Pittsburgh, Pennsylvania

Cost Factor analysis

- Assuming an average of 4 hours of monitoring time per surgical case, the savings realized in this group of patients was estimated to be \$1,024,754. This study demonstrates that decompression and reconstruction for symptomatic cervical spine disease without IOM may reduce the cost of treatment without adversely impacting patient safety.

J Neurosurg Spine. 2011 Nov 11. [Epub ahead of print]

Cervical decompression and reconstruction without intraoperative neurophysiological monitoring.

Traynelis VC, Department of Neurosurgery, Rush University Medical Center, Chicago, Illinois

Role of EMG in minimally invasive Sx

- In minimally invasive approaches to the spine, the use of EMG IOM might provide additional safety, such as percutaneous pedicle screw placement, where visualization is limited compared with conventional open procedures. In addition to knowledge of the anatomy and image guidance, directional EMG IOM is crucial for safe passage through the psoas muscle during the minimally invasive lateral retroperitoneal approach.

Spine (Phila Pa 1976). 2010 Dec 15;35(26 Suppl):S368-74.

Electromyographic monitoring and its anatomical implications in minimally invasive spine surgery.

Uribe JS Department of Neurosurgery and Brain Repair, University of South Florida, Tampa, FL, USA

MEP in glioma and pediatric population

- **Intraoperative monitoring of motor evoked potentials in very young children < 3yrs**

J Neurosurg Paediatric. 2011 Apr;7(4):331-7. Fulkerson DH Neuro-Spine Program, Division of Paediatric Neurosurgery, Texas Children's Hospital, Department of Neurosurgery, Baylor College of Medicine, Houston, Texas 77030, USA.

- **Predictive value and safety of intraoperative neurophysiological monitoring using motor evoked potentials in glioma surgery.**

Neurosurgery.2011 Nov 3. [Epub ahead of print]

Krieg SM Department of Neurosurgery, Technische Universität München, Munich, Germany
Sandro

MEP + SSEP

- **Preventing position-related brachial plexus injury with intraoperative somatosensory evoked potentials and transcranial electrical motor evoked potentials during anterior cervical spine surgery.**

Am J Electroneurodiagnostic Technol. 2011 Sep;51(3):198-205.

Jahangiri FR Impulse Monitoring, Inc., Columbia, Maryland, USA.

MEP in aneurysm Sx

- **The use of motor evoked potential monitoring during cerebral aneurysm surgery to predict pure motor deficits due to subcortical ischemia.**

Clin Neurophysiol. 2011 Apr;122(4):648-5 Guo L Neurophysiological Monitoring Service, University of California, San Francisco, Box 0220, 533 Parnassus Avenue, U-491, San Francisco, CA

- **The value of intraoperative neurophysiological monitoring in tethered cord surgery.**

Childs Nerv Syst.2011 Sep;27(9):1445-52. Epub 2011 May 3.

Hoving Department of Neurosurgery, University Medical Centre Groningen, The Netherlands.

External Anal/Urethral sphincter EMG Monitoring

- Lumbosacral surgery for tumor resection/ detethering
- S2-S4 nerve roots monitored
- Insertion of urethral ring electrode facilitated by 2-way foley's with electrode applied 1-2 cm proximal to the the inflated ballon
- Insertion of anal sphincter electrode is performed similar to rectal temperature probes.

FACTORS AFFECTING EPS RECORDING UNDER ANESTHESIA

- HYPOTHERMIA
- HYPOXIA
- HYPOTENSION/ISCHEMIA
- ANESTHETIC AGENTS
- SURGICAL FACTORS: INJURY-COMPRESSION-RETRACTION

ANESTHETIC EFFECTS ON EPS

- LATENCY DELAY
- AMPLITUDE REDUCTION (EXCEPT ETOMIDATE AND KETAMINE)
- VARIABLE AMONG AGENTS
- WORSE IN INHALATIONAL AGENTS AND DOSE DEPENDANT
- ADDITIVE EFFECTS OF AGENTS
- VEP > SSEP > BAER

Compound Nerve Action Potential (CNAP)

- Combined activity of all the axons taken together
- Each individual axon shows all/none phenomenon but CNAP varies continuously to a maximum amplitude
- Amplitude \propto Numbers of axons that fire together
- CNAP is a reflection of general histology of a particular nerve
- In an effort to record the *difference* in potential that is the CNAP, we must provide contact with the nerve at the active length of the nerve, as well as contact with the nerve at a point that does not contain active axons.

CNAP Contd..

- The distance between the stimulating and recording electrodes also has limitations. Stimulus artifact is a common problem encountered in operative recordings.
- When the distance between the stimulating and recording electrodes is less than approximately 2 cm, the amount of stimulus artifact becomes so great that it can obscure a small CNAP. Particularly important in children.
- Another source of excessive stimulus artifact is the wires connected to the electrodes. When both the stimulating and recording wires exit the surgical field together and in close proximity, artifact is induced in the recording wires from the stimulating wires

Cont...

- When relatively long-duration stimulus pulses are used, on the order of 0.2 msec, stimulus artifact is considerable. Reducing stimulus duration to a value between 0.02 and 0.05 msec provides considerably less stimulus artifact.
- Very proximal avulsive nerve injuries are monitored better by SSEP/MEP.

Methods for Cranial Nerve Monitoring

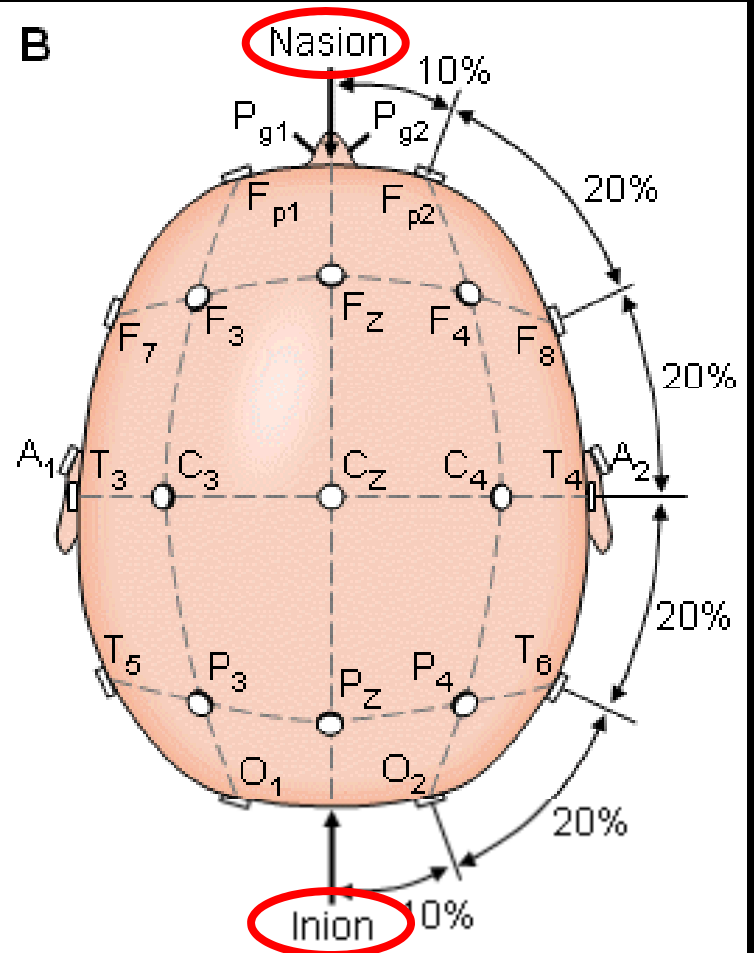
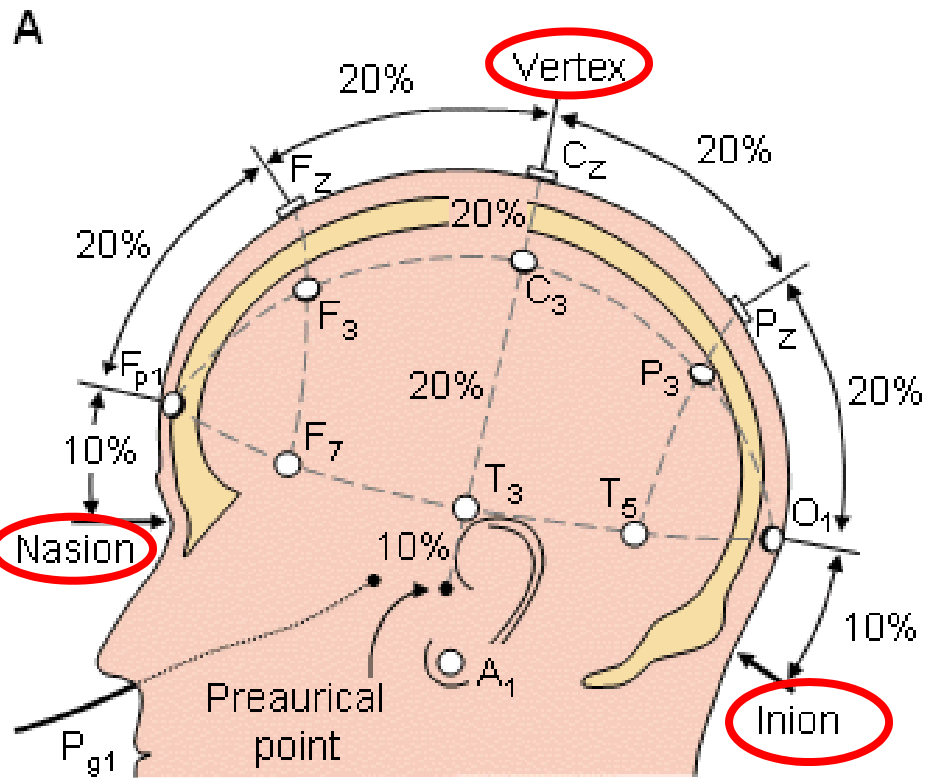
II	Optic	sensory: VEP
III	Oculomotor	motor: inferior rectus <i>m</i>
IV	Trochlear	motor: superior oblique <i>m</i>
V	Trigeminal	motor: masseter and/or temporalis <i>m</i>
VI	Abducens	motor: lateral rectus <i>m</i>
VII	Facial	motor: obicularis oculi and/or obicularis oris <i>m</i>
VIII	Auditory	sensory: ABR
IX	Glossopharyngeal	motor: posterior soft palate (stylopharygeus <i>m</i>)
X	Vagus	motor: vocal folds, cricothyroid <i>m</i>
XI	Spinal Accessory	motor: sternocleidomastoid <i>m</i> and/or trapezius <i>m</i>
XII	Hypoglossal	motor: tongue, genioglossus <i>m</i>

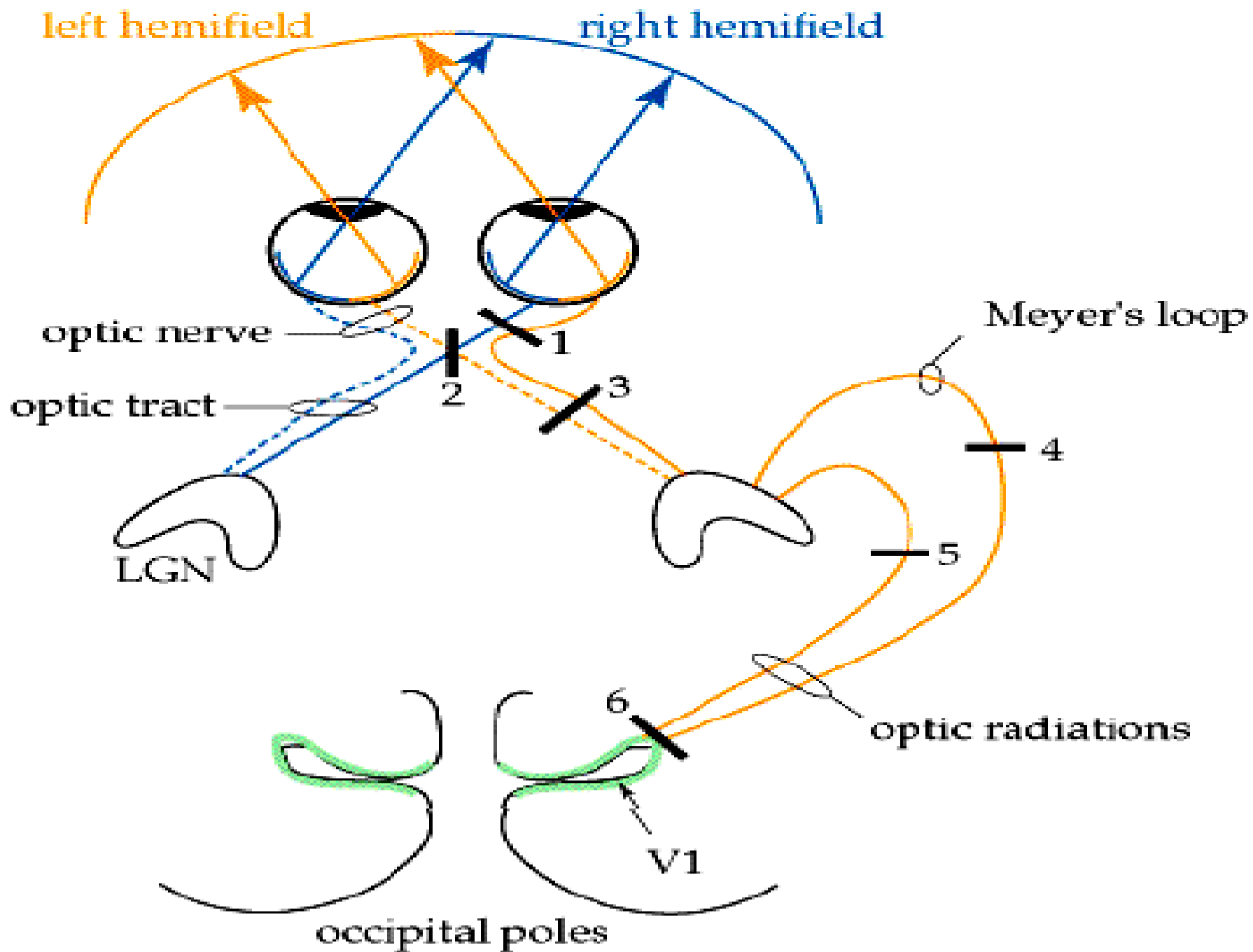
Introduction - VEP

- The VEP tests the function of the visual pathway from the retina to the occipital cortex.
- It assesses the integrity of the visual pathways from the optic nerve, optic chiasm, and optic radiations to the occipital cortex.
- Visual Cortex (occipital lobe)
The generator site is believed to be the peristriate and striate occipital cortex

Cont..

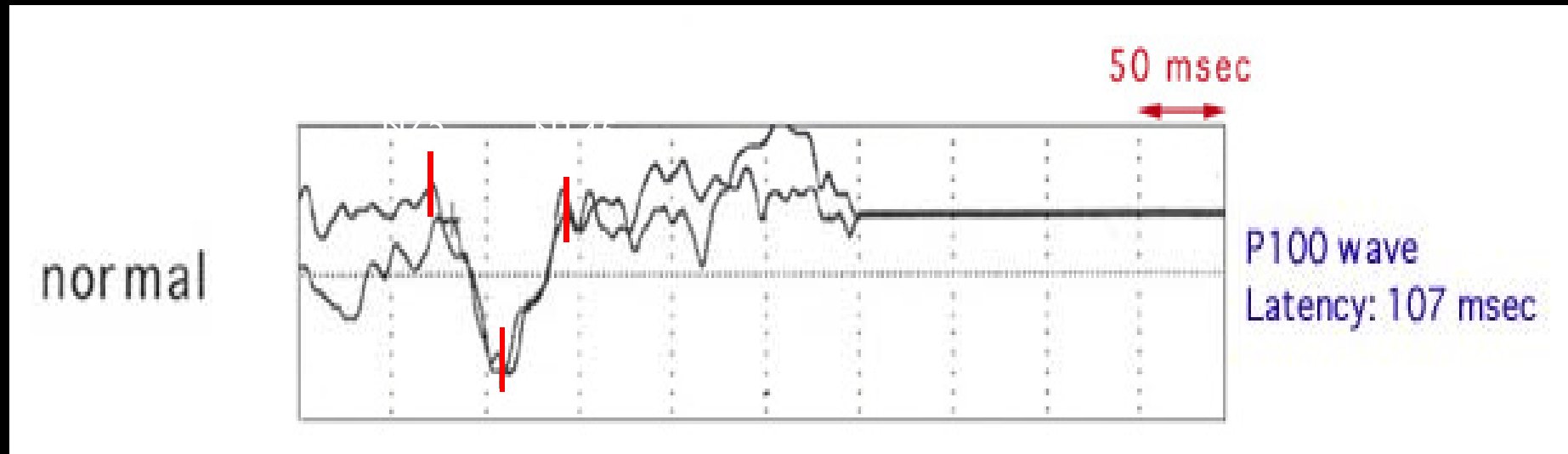
- The VEP is very useful in detecting an anterior visual conduction disturbance.
- However, it is not specific with regard to etiology.
For example a tumor compressing the optic nerve, an ischemic disturbance, or a demyelinating disease may cause delay in the P100.
- Apply three scalp electrodes at;
Oz : 2cms above the inion.
Cz : at vertex
Fz : on frontal bone.





Waveforms (The NPN complex)

- The initial negative peak (N1 or N75)
- A large positive peak (P1 or P100)
- Negative peak (N2 or N145)



Maximum Value for P100

- P100 is 110 milliseconds (ms) in patients younger than 60 years
(it rises to 120 ms thereafter in females and 125 ms in males.)
- Interocular P100 latency difference is upto 5 – 6 msec. > 10 ms is gross abnormality.
- Negative components of NPN complex may be absent even in normal subject. The only persistent wave is P100.

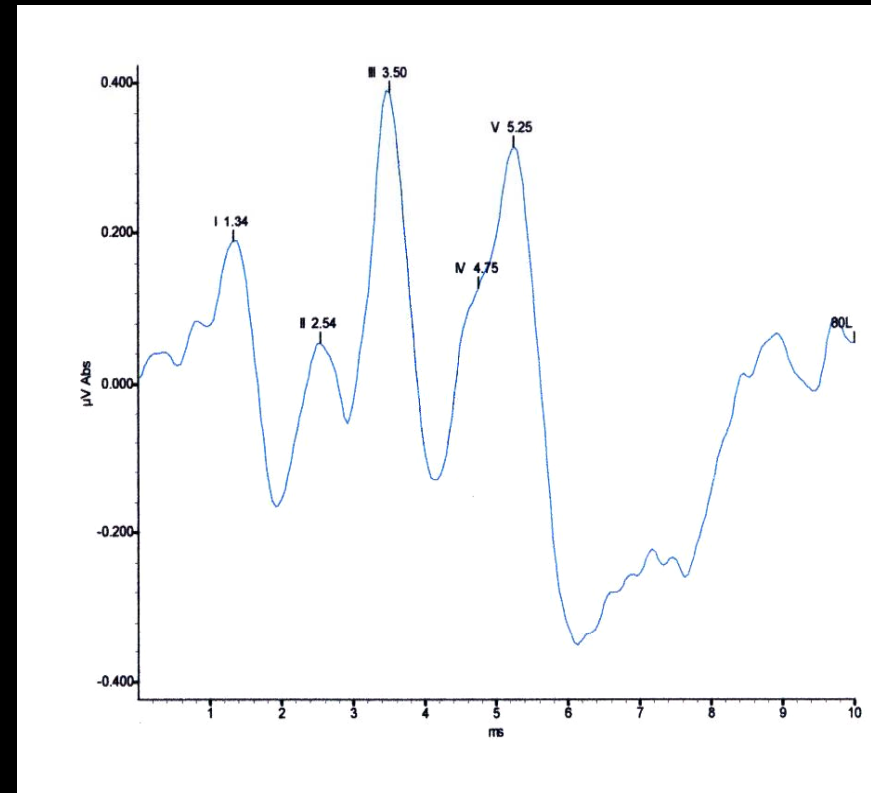
Limitation



- Cannot predict visual field defects

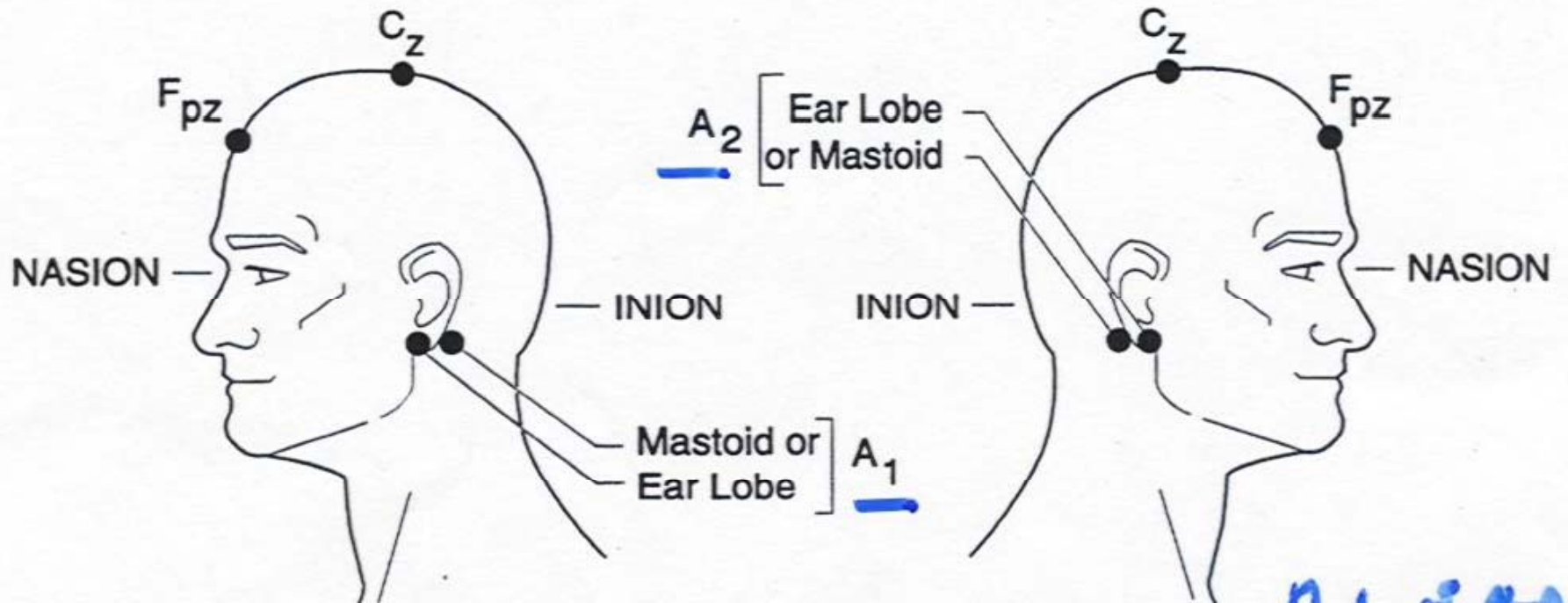
What is an ABR?

- The Auditory Brainstem Response is the representation of electrical activity generated by the eighth cranial nerve and brainstem in response to auditory stimulation



How is an ABR recorded?

- Electrodes are placed on the scalp and coupled via leads to an amplifier and signal averager. EEG activity from the scalp is recorded while the ear(s) are stimulated via earphones with brief clicks or tones.
- A series of waveforms unique to the auditory neural structures is viewed after time-locking the EEG recording to each auditory stimulus and averaging several thousand recordings.



Interpretation

- Positive deflections are termed waves I-VII. Waves I, III, and V are the waves most consistently seen in healthy subjects (obligate waves). Wave V is the most reliably seen wave, particularly in patients with hearing impairment or undergoing surgery. A shift in latency of 1 millisecond or a drop in amplitude of 50% could be significant and should be reported to the surgeon.

Clinical uses

- Cerebellopontine angle surgery: This includes surgery for acoustic neuroma or meningioma, or for microvascular decompression for tic douloureux or hemifacial spasm.
- Important parameters to monitor include peak amplitude of waves III and V, latency of wave V, latency of waves I-V, and latency of waves I-III. If changes occur, they may be due to improper retraction on the cerebellum and brain stem; these may be reversible with a change of position of the retractors by the surgeon.

Intra-operative EEG - Technique

- Intraoperative scalp EEG recordings can be performed using standard electrodes and paper or digital EEG machines.
- Because of the difficulty of re-applying electrodes in the operating room, a secure scalp-electrode interface must be assured, usually by using collodion with a cup electrode.
- In certain circumstances, an electrode cap or needle electrodes may be useful. Standard 10-20 electrode placement is used typically, and signals are recorded in 8-32 channels of bipolar, with or without referential, derivations.
- Because of the need to monitor beta activity, high-frequency filters less than 35 Hz should not be used

Interpretation

- The most important requirement for intraoperative EEG recording is knowledge of expected changes with deepening levels of anaesthesia.
- Premedication with barbiturates or benzodiazepines causes increased beta activity and then successively increased slowing.
- With induction, frontal intermittent delta activity (FIRDA) often is observed, or perhaps transient (< 1 min) burst suppression if induction is rapid.
- Then diffuse faster activity is seen, typically slowing from beta to alpha frequencies, superimposed on variable theta and delta, depending on depth of anaesthesia. Still deeper stages sometimes can produce burst suppression.

Intra-operative changes

- The most important lateralized or localized changes include loss of fast activity along with increase in slow activity.
- These lateralized or localized changes generally reflect focal decrease in cerebral blood flow resulting from either acute change in vessel calibre or hypotension in the setting of a fixed stenosis.

Uses

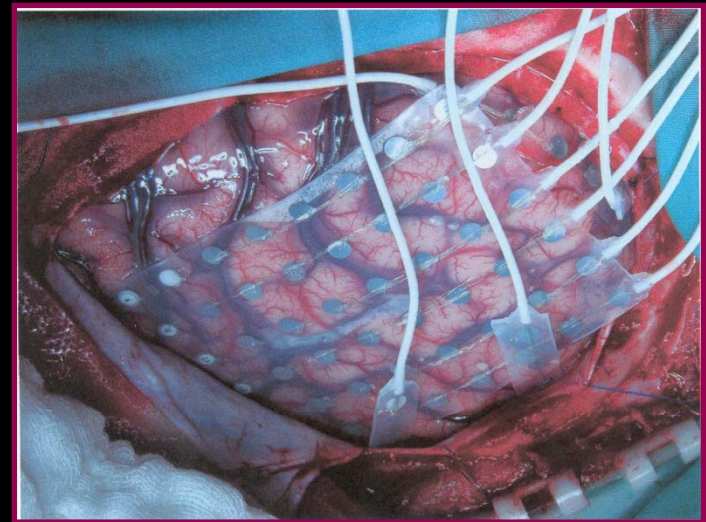

- The most common use of scalp EEG for intraoperative monitoring is during carotid endarterectomy. EEG changes are reliable guides to acute changes in cerebral blood flow that occur, for example, during carotid cross-clamping. These usually are seen within 30 seconds and indicate a need for shunting.
- Embolization during or after the procedure also can manifest as lateralized or localized EEG changes.
- Other uses of scalp EEG include during aneurysm repair when carotid clamping is required and during hypothermic circulatory arrest for cardiac surgery.

Electrocorticography -- *Technique*

- Intraoperative ECoG can be recorded by using saline-soaked cotton or carbon ball electrodes attached by flexible wires to a frame fixed to the skull,
- or by using stainless steel or platinum disc electrodes embedded in silastic, similar to those used routinely for long-term extra operative recording.
- The signal is recorded with a standard paper or digital EEG machine and displayed in bipolar and/or referential derivations.
- Optimal sensitivity settings usually range between 20 and 70 $\mu\text{V}/\text{mm}$, with a high-frequency filter of 70 Hz

Use of ECoG for identification of functional brain areas

- ECoG stimulations: determine critical location by disrupting the function.
- ECoG recordings: mapping endogenous cortical function, reflecting normal cortical function.



Interpretation

- Epileptiform spikes are significantly sharper at the cortical surface than at the scalp and often have durations of only 10-20 milliseconds.
- Cortical regions producing frequent spikes, occurring periodically to continuously, almost certainly need to be resected for optimal seizure outcome.
- As noted later, deep anaesthesia with most agents suppresses spikes, while methohexital boluses of up to 1 mg/kg can at times be activating. In awake patients, encouragement to relax and become drowsy can be a more physiologic activation method.

Clinical uses

- To ameliorate seizures. In lesional cases, seizure outcome is most dependent on complete lesion resection, but removing surrounding areas that show very frequent spiking probably can improve outcome further and also may help if the lesion cannot be removed completely.
- In the special case of cortical dysplastic lesions, ictal or near-ictal ECoG patterns are common, and may guide resection when the margins are not clear on direct inspection or on neuroimaging.

Uses Cont...

- Nonlesional cases usually rely on extraoperative recording of seizure onsets using indwelling depth or subdural electrodes, but margins sometimes can be refined using intraoperative ECoG
- In the case of mesial temporal lobe epilepsy, ECoG recorded from the lateral temporal cortex is of questionable utility, but recording from the parahippocampal region can assist in determining the posterior resection margin.

Cortical Electrical Stimulation

Technique

- "Mapping" of functional cortex by electrical stimulation still is considered the criterion standard of determining areas whose resection risks causing neurologic deficits.
- Usually bipolar stimulation is performed with either the same silastic embedded disc electrodes used for recording,
 - or a movable, hand-held bipolar stimulator including 2 closely spaced spherical electrodes.
- The stimulus is an alternating square-wave pulse of 0.3-2 milliseconds duration at 50-75 Hz, with currents between 0.5-15 milliamperes applied for 4-8 seconds.

Technique Cont...

- In the lightly anesthetized patient, motor cortex can be localized, but the patient must be awake for testing sensation, language, and at times memory formation. Motor-inhibitory areas also can be localized by using continuous motor tasks. Language tasks can include spontaneous speech, recitation, reading, and naming.

Interpretation

- Any stimulated area that produces spontaneous movement or sensation should be spared resection if possible. Resection of motor-inhibitory areas also should be minimized, although the deficits produced are usually temporary.
- Language problems can be minimized by avoiding resection of areas within 1 cm of those producing deficits on any language task

Clinical uses

- Cortical electrical stimulation should be considered whenever resection in the vicinity of eloquent cortex is planned. It is used in conjunction with removal of neoplastic, vascular, or other lesions, or of structurally intact cortex for relief of epilepsy.

Future Developments

- Possibility of visualizing and quantifying myelinated axons directly under microscope in vivo – using techniques like – CARS (Coherent Anti-stokes Raman Scattering) Sensitive to lipid rich cells : Adipocytes, Schwann cells, Oligodendrocytes without using exogenous labeling
- This technique uses CH-Raman vibration that is present in lipids by exciting it with two lasers of different wavelengths such that the difference in their frequency corresponds to the frequency of vibration.
- Using Second-Harmonics generation imaging it may be possible to directly visualize membrane depolarization and action potentials

Conclusion

- Although there is extensive level-II evidence to support the use of intra-operative monitoring in neurosurgery (especially in spine), Level I evidence is lacking
- Moreover it is doubtful that large prospective, randomized, blinded, and controlled trials of intra-operative monitoring will be undertaken because of logistic, ethical and potential medico-legal concerns.



Questions ?